

# RetinOpTIC – Automatic Evaluation of Diabetic Retinopathy

Bruno Lay<sup>1</sup>, Ronan Danno<sup>1</sup>, Gwénoél Quéllec<sup>2</sup>, Etienne Decencière<sup>3</sup>, Ali Erginay<sup>4</sup>, Pascale Massin<sup>4</sup>, Alexandre Le Guilcher<sup>5</sup>, Mathieu Lamard<sup>2</sup>, Robin Alais<sup>3</sup>, Béatrice Cochener<sup>6</sup>  
 (1) ADCIS SA, Saint-Contest, France – (2) Inserm, Brest, France – (3) CMM, Fontainebleau, France – (4) AP-HP, Paris, France – (5) Evolucare, Le Pecq, France – (6) Service Ophtalmologie CHRU Brest, France

## PURPOSE

The aim of the RetinOpTIC project is to perform mass screening of color fundus images assessing the presence of Diabetic Retinopathy (DR). Algorithm performance is evaluated on the Messidor-2 image database, and compared to competitive algorithms which are already CE marked and FDA approved.

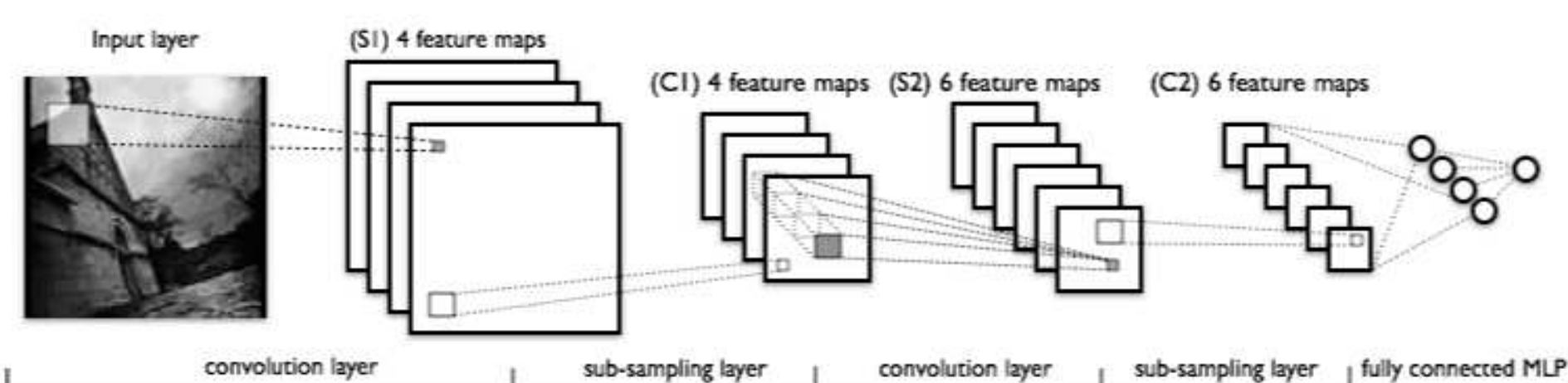
## METHODS

Based on Artificial Intelligence (AI) solutions, referable DR is detected using convolutional neural networks (CNNs). The solution includes first the automatic assessment of the quality of the photography, and then the DR screening. Referable DR is defined as moderate non proliferative DR, or more severe with or without macular edema (ME).

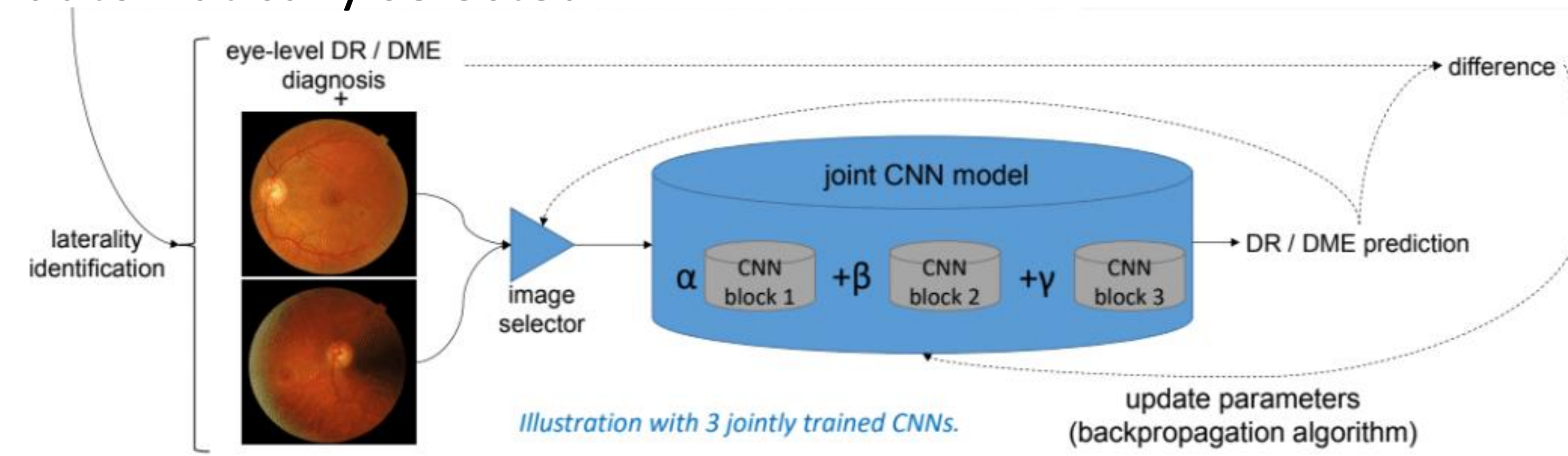
About 10% of images acquired in e-medicine networks are considered as ungradable for quality reasons. It is important to recapture images while patients are still present. An AI solution was developed determining if the macula and surrounding vessels are visible, as well as an assessment of the global sharpness of the image, the local sharpness, and the density of the vessel network.

Once the image is correct, a set of CNNs produces one referral decision. CNNs were trained on images from the OphDiat database, captured by a network of Paris hospitals and primary care settings.

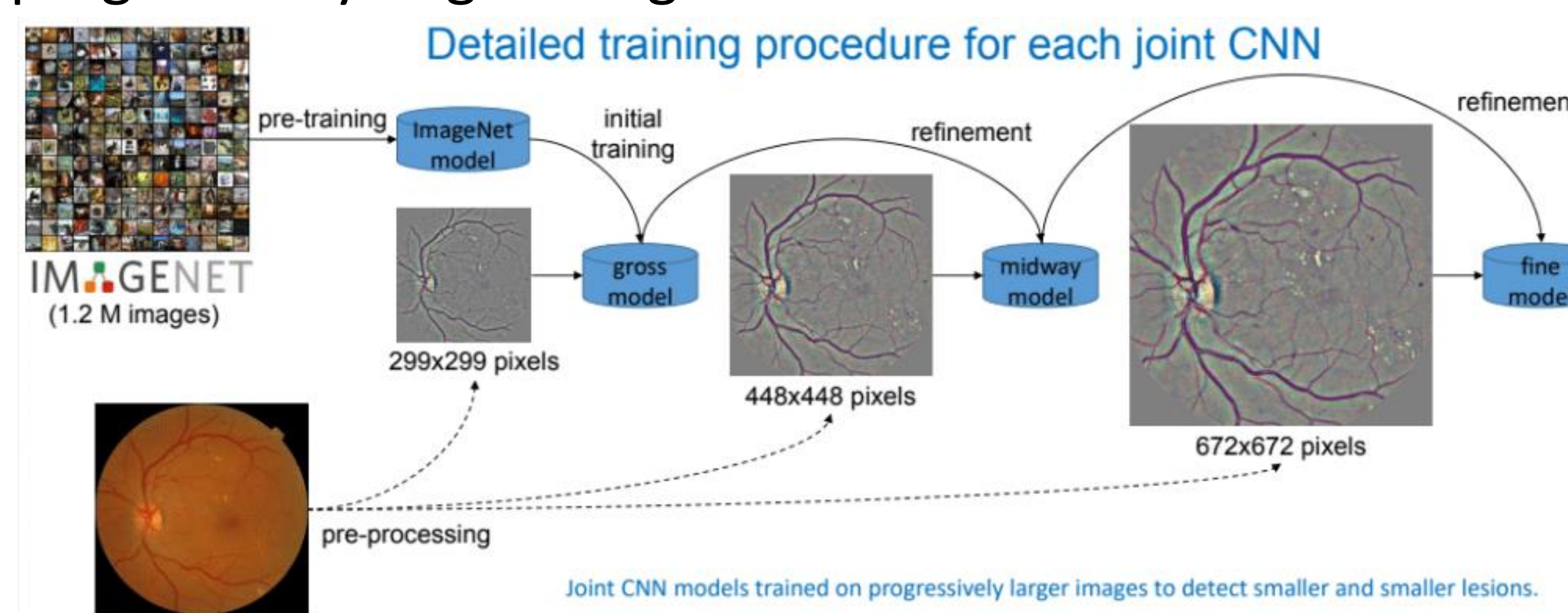
Unlike competing AI solutions, CNNs are jointly trained in such a way they are complementary with one another. The proposed set of CNNs was trained on more than 80,000 color fundus images of different qualities and sizes.



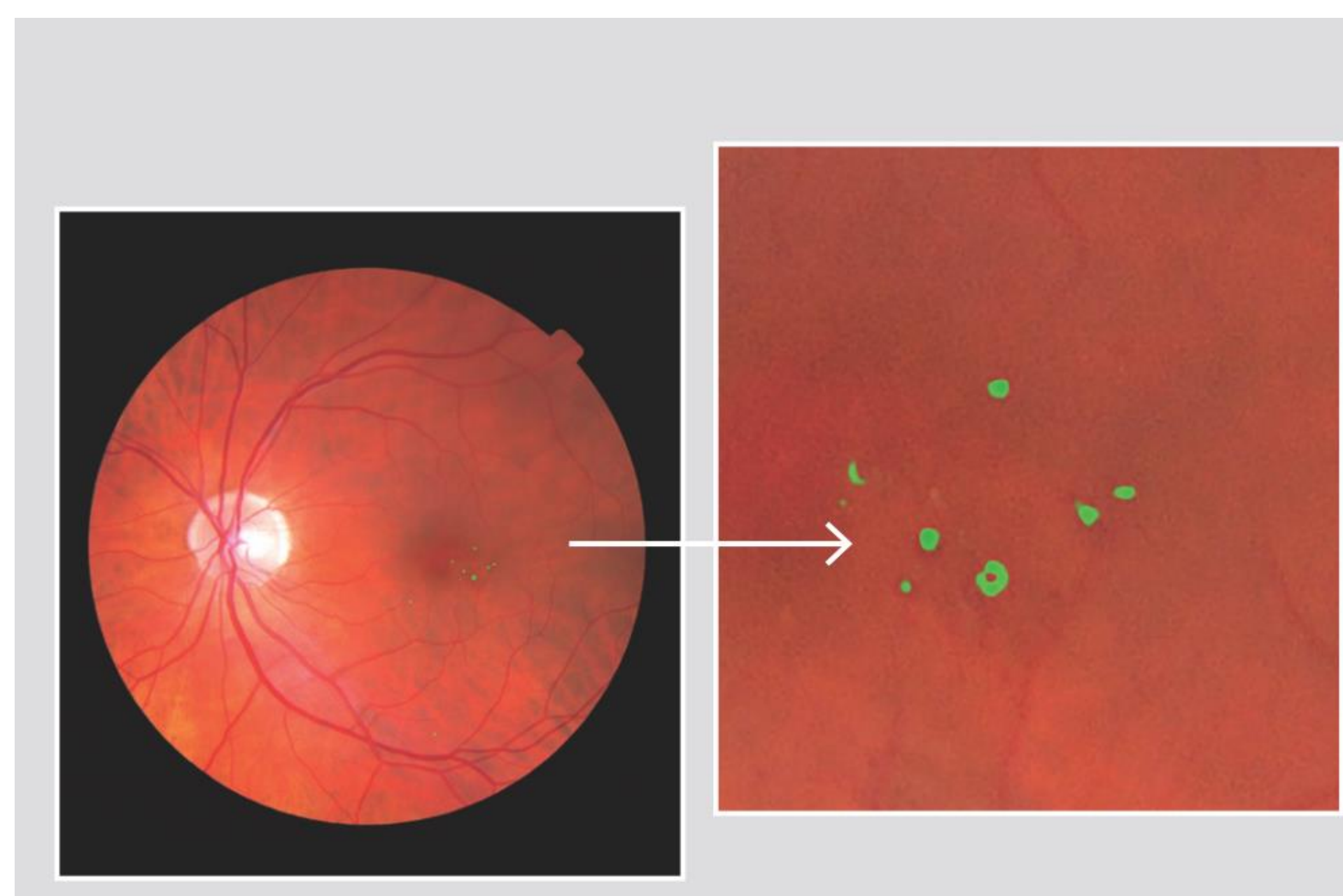
The proposed CNN ensemble was trained to process a varying number of images per eye. During training and inference, the most pathological image in each eye was automatically selected.



To be able to detect smaller and smaller lesions such as microaneurysms, joint CNN models were trained on progressively larger images.



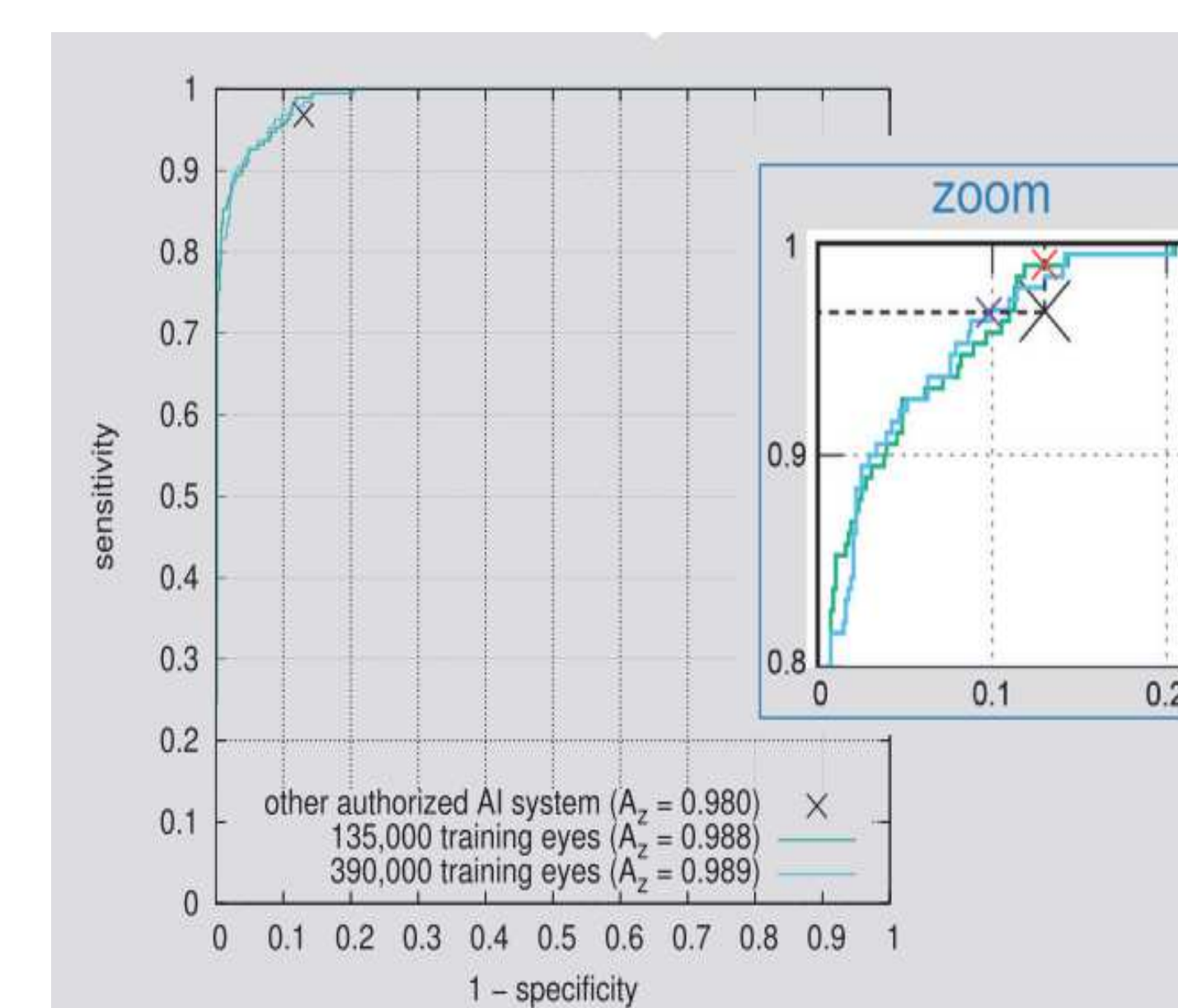
Thanks to a proposed heatmap generation method<sup>1</sup>, patterns detected by each CNN could be overlaid on the associated image for pathology visualization. The figure below shows the detection of hemorrhages and microaneurysms.



<sup>1</sup> Quéllec et al. Deep image mining for diabetic retinopathy screening. Med Image Analysis (2017) 39: 178-193

## RESULTS

The quality criterion was evaluated on 6,098 images annotated by two experts. It reached a value of 96.4%. Referable DR was detected with an area under the ROC curve of 0,988 on the Messidor-2 database, using the University of Iowa's reference standard (sensitivity = 99.0%, specificity = 87.0%). Results were better than previously reported systems, evaluated under the same conditions. In addition, the system could produce lesion-specific heatmaps, while previously reported CNN heatmaps did not allow lesion differentiation.



- Detector trained on OphDiat database. Performance evaluated on Messidor-2 dataset
- Number of test images: 1,748 images from 874 patients
- Both algorithms ran in less than 1 second on an Intel Core i7 CPU@3.7 GHz

If "specificity = 87.0 %":

- Sensitivity = 96.8 % for IDx
- Sensitivity = 99.0% for RetinOpTIC

If "sensitivity = 96.8%":

- Specificity = 87.0 % for IDx
- Specificity = 90.2 % for RetinOpTIC

<http://www.adcis.net/en/applications/automatic-grading-diabetic-retinopathy>

## CONCLUSION

The proposed jointly trained CNN ensemble improves fully automatic detection of referable DR adding a real-time assessment. It provides more accurate predictions than competitive systems in less than a second. It is now available as a CE marked solution called OphtAI.