

INTRODUCTION

Retinal thickness and volume analysis by Optical Coherence Tomography has recently become a reliable way of monitoring macular disease activity.

Nevertheless, retinal volume can consist of several separate anatomical sections that can vary independently and cannot always be analyzed as a whole.

We aim to describe and validate the first results of **PED volume quantification** by a new software (ReVA) and the follow up results after anti VEGF treatment (Figure 1).

METHODS

We included in a prospective fashion patients presenting with **vascularized PEDs** secondary to exudative AMD, previously diagnosed on the basis of multimodal imaging.

All patients had undergone complete ophthalmological examination, fluorescein angiography and ICG angiography. Spectral Domain Optical Coherence Tomography (SD-OCT) on Enhanced Depth Imaging (EDI) mode (Spectralis HRA+OCT, Heidelberg Engineering GmbH, Heidelberg, Germany) was performed, with an acquisition of a 30 degree retinal volume scan consisting of 61 lines centered on the fovea with an averaging of 9 frames per scan.

This information was exported in .XML format to the ReVA software. The information was anonymized. A **semi automatic** analysis of PED volume was performed by **three independent readers** (OS, VC, RBG), twice, at the beginning and end of a 15 day period (Figure 2)

The software allows for **semi automated delineation of PED limits** on a two dimensional scan basis, and afterwards calculations are performed to present **PED volume** results in cubic millimeters (Figure 3)

The results are presented in a **3D volume representation** that can be manipulated to be seen from various angles (Figure 4)

The **Bland and Altman** assessment for agreement was used to compare intra and inter-observer observations.

RESULTS

We included **20 eyes** of 20 patients presenting with vascularized PED.

The Bland-Altman analysis indicates that the 95% limits of agreement between the inter and intra observer measures ranged in average from 0.99 to 1.00 with an **average correlation of 0.99** (Figure 5).




Figure 1. ReV analyzer Software Homepage

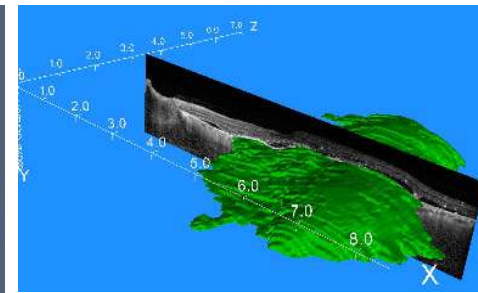


Figure 4. Final 3D PED volume representation

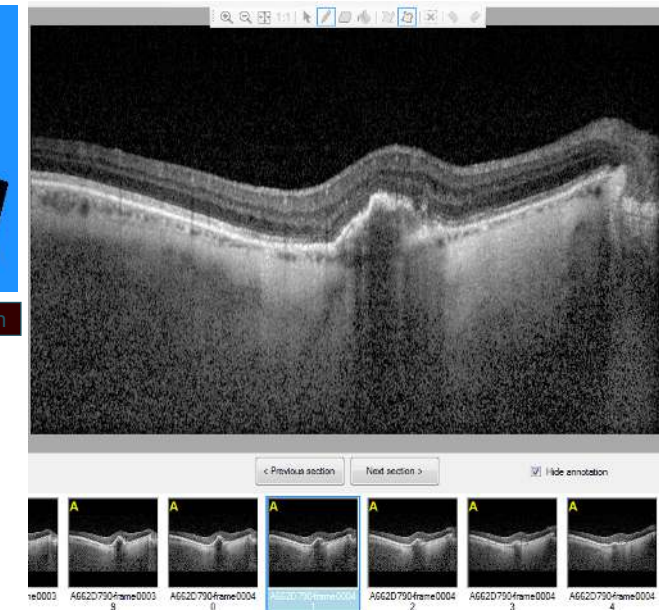


Figure 2. Selection of OCT B-scan

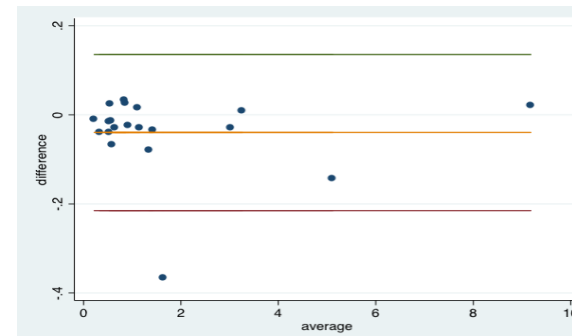


Figure 5. Bland-Altman analysis for inter-observer agreement.

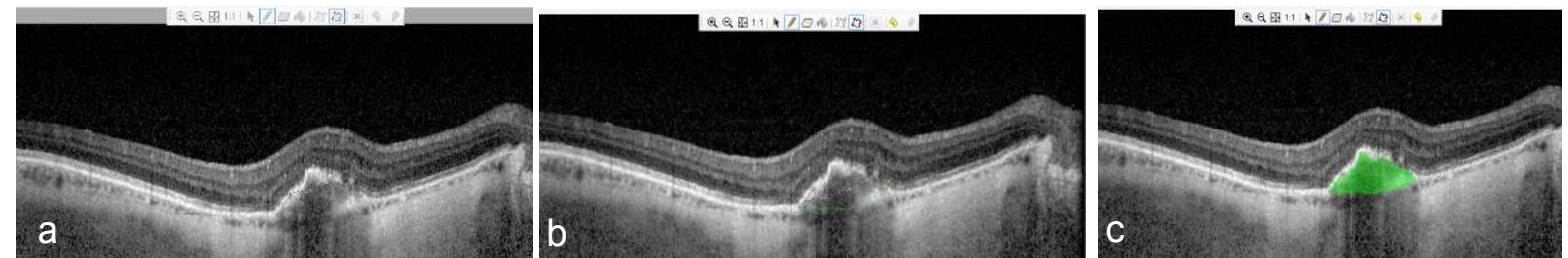


Figure 3. Semi automatic progressive PED demarcation (a,b) on OCT B-scan. Final PED demarcation on OCT B-scan (c)

DISCUSSION - CONCLUSION

ReVAnalyzer is a reliable tool that can assist in the analysis of PED volume with high precision.

This type of separate retinal volume analysis can be of help for monitoring disease activity and therapeutic response in AMD.